

Received: 12.02.2011  
Accepted: 30.06.2011

A – Study Design  
B – Data Collection  
C – Statistical Analysis  
D – Data Interpretation  
E – Manuscript Preparation  
F – Literature Search  
G – Funds Collection

# THE ROLE OF NEUROPSYCHOLOGICAL ASSESSMENT IN THE DETECTION OF EARLY SYMPTOMS IN FRONTOTEMPORAL DEMENTIA AND PARKINSONISM LINKED TO CHROMOSOME 17 (FTDP-17)

Emilia J. Sitek<sup>1,2(A,B,D,E,F,G)</sup>, Anna Barczak<sup>3(A,B,D,E,F)</sup>,  
Ewa Narożańska<sup>1,2(A,B,D,E,F,G)</sup>, Małgorzata  
Chodakowska-Żebrowska<sup>3(B,E)</sup>, Barbara  
Jasińska-Myga<sup>4(D,E)</sup>, Bogna Brockhuis<sup>5(B,D,E)</sup>,  
Mariusz Berdyński<sup>6(B,D,E)</sup>, Dariusz  
Wieczorek<sup>7(D,E)</sup>, Cezary Żekanowski<sup>6(D,E)</sup>,  
Seweryna Konieczna<sup>8(B,E)</sup>, Maria  
Barcikowska<sup>3,6(D,E)</sup>, Zbigniew K. Wszolek<sup>9(D,E)</sup>,  
Jarosław Sławek<sup>1,2(A,B,D,E,G)</sup>

<sup>1</sup> Department of Neurology, St. Adalbert Hospital, Gdansk, Poland

<sup>2</sup> Department of Neurological and Psychiatric Nursing, Medical University of Gdansk, Gdansk, Poland

<sup>3</sup> Department of Neurodegenerative Diseases, Neurology Clinic, MSWiA Hospital, Warsaw, Poland

<sup>4</sup> Department of Neurology, Medical University of Silesia, Katowice, Poland

<sup>5</sup> Department of Nuclear Medicine, Medical University of Gdansk, Gdansk, Poland

<sup>6</sup> Department of Neurodegenerative Disorders, Mossakowski Medical Research Center, Polish Academy of Sciences, Warsaw, Poland

<sup>7</sup> Department of Rehabilitation, Medical University of Gdansk, Gdansk, Poland

<sup>8</sup> Department of Developmental Neurology, Medical University of Gdansk, Gdansk, Poland

<sup>9</sup> Department of Neurology, Mayo Clinic, Jacksonville, Florida, USA

## Background:

**SUMMARY**  
Frontotemporal dementia and parkinsonism linked to chromosome 17 is a rare variant of frontotemporal dementia, characterized by behavioral, cognitive and motor dysfunctions. The onset of the disease is variable. However, cognitive and behavioral changes usually precede motor symptoms. Early

**Case study:**

abnormalities can be identified by means of smell tests, motor speech assessment and neuropsychological evaluation.

We provide a clinical description of a 48-year-old man with a P301L *MAPT* mutation, who presented with subtle neuropsychological deficits and depression, without behavioral or motor changes when diagnosed with FTDP-17. The results of two neuropsychological assessments (baseline and follow-up) are presented, addressing both global and specific cognitive functions. The results showed early phonemic fluency deficits, followed by language and procedural memory impairment. In addition, the qualitative analysis of the Rey/ Taylor Complex Figure Test and picture description trials (both oral and written) provided further evidence for cognitive dysfunction in this patient. Early verbal fluency deterioration, possibly linked to both executive dysfunction and language breakdown, is consistent with previous reports.

**Conclusions:**

Our data suggests that a comprehensive neuropsychological assessment in individuals with FTDP-17 is highly recommended and should include both quantitative and qualitative measures.

**Key words:** frontotemporal dementia, executive dysfunction, verbal fluency

---

## INTRODUCTION

Frontotemporal dementia and parkinsonism linked to chromosome 17 (FTDP-17) is a rare neurodegenerative disorder with a triad of behavioral, cognitive and motor symptoms. A common clinical presentation of the disorder was defined at a consensus conference in Ann Arbor in 1996 (Foster et al., 1997). During that meeting, it was demonstrated that in many patients with FTDP-17 cognitive and behavioral deficits precede motor symptoms. The most typical behavioural abnormalities include disinhibition, apathy, poor impulse control, repetitive and stereotyped behaviour, aggressiveness, hyperorality and early loss of personal awareness. Interestingly, it has also been shown that these behavioral disturbances are closely linked to executive dysfunction, e.g. deficient mental-flexibility, impaired foresight and planning, and disturbed cognitive control. Executive deficits usually appear before other cognitive domains are affected. Reduction in spontaneous speech is progressive, eventually leading to mutism. Echolalic speech may also be present. Later in the course of the disease, patients may also exhibit psychotic symptoms. However, despite this general clinical description, no definitive diagnostic criteria for FTDP-17 have yet been proposed. It should be pointed out that, before the consensus conference in 1996, different names were used in the literature to describe families with FTDP-17 phenotype,

typically describing the predominant clinical manifestation: Duke family 1684, Seattle family A, DDPAC (*disinhibition-dementia-parkinsonism-amyotrophy complex*), PPNB (*pallido-ponto-nigral degeneration*), MSTL (*multiple system tauopathy with dementia*), HDDL (*hereditary dysphasic disinhibition dementia*), PSP (*progressive subcortical gliosis*) and others (Foster et al., 1997).

FTDP-17 is associated with mutations in the microtubule-associated protein tau (*MAPT*) and progranulin (*GRN*) genes. Regardless of the underlying pathology, the clinical course of FTDP-17 is similar. Patients with either the *MAPT* or the *PGRN* mutation present with personality and behavioral changes, executive dysfunction, language impairment and less pronounced memory disturbances and visuospatial impairment (more evident in the *PGRN* mutation), together with limb apraxia and parkinsonism. In comparison to the *MAPT* mutation, the *PGRN* mutation frequently manifests clinically as progressive nonfluent aphasia and Alzheimer's disease, with lateralized changes on neuroimaging (Kelley et al., 2009). Pathological findings reveal tau-positive inclusions in the *MAPT* mutation and ubiquitin-positive inclusions in the *PRGN* mutation, which seems to be the most salient differentiating factor between these two forms of FTDP-17 (Boeve & Hutton, 2008).

Recently, the first Polish family (Gdansk family) was described with FTDP-17 due to the P301L mutation in *MAPT* (Narożańska et al., 2011). In one of the patients from this family, unilateral neglect and personality changes were also reported (Sitek et al., 2009; Sitek et al., 2010a).

## NEUROPSYCHOLOGICAL ASSESSMENT OF GENE-POSITIVE FTDP-17 INDIVIDUALS

Only recently have researchers become interested in genetic testing in asymptomatic individuals from families with FTDP-17 (McRae et al., 2001), which hinders group studies in this population. The results of both longitudinal case studies and small group studies indicate that before the onset of behavioural and neurological symptoms the patients' performance is frequently deficient in executive and attentional tasks (Geschwind et al., 2001; Ferman et al., 2003). Decreased phonemic fluency has been found in all presymptomatic studies and seems to predict the onset of full-blown FTDP by 1-2 years in patients with N279K tau mutation (Ferman et al., 2003). Motor speech abnormalities, such as vocal instability (tremor and flutter), vocal modulation deficits (monopitch), speech slowing (Arvanitakis et al., 2007; Liss et al., 2006), as well as anosmia (smell loss) are also markers of the disease onset (Arvanitakis et al., 2007).

Data from the literature suggests that phonemic fluency trials, the Trail Making Test, Digit Span, the Wisconsin Card Sorting Test and the Stroop Test can be useful for early detection of impairment in the neuropsychological evaluation of preclinical FTDP-17 (Geschwind et al., 2001; Ferman et al., 2003). The methodology of previous studies with presymptomatic and early symptomatic FTDP-17 patients is presented in Table 1. However, little is still known about these patients'

Table 1. Methodology of neuropsychological assessment in studies with FTDP-17 presymptomatic or early symptomatic individuals

	Geschwind et al., 2001	Ferman et al., 2003; Arvanitakis et al., 2007	Alberici et al., 2004
number of cases	10	5	1
carried mutation	P301L	N279K	P301L
<i>global cognitive status</i>			
Mini-Mental State Examination (MMSE)	-	-	+
<i>semantic memory</i>			
Information from WAIS-R	+	-	-
<i>abstract thinking</i>			
Similarities from WAIS-R	+	-	-
<i>attention and working memory</i>			
Trail Making Test (TMT)	+	+	-
Digit Span	+	-	+
spatial span	-	-	+
Attention matrices	-	-	+
<i>language function</i>			
naming -Boston Naming Test	+	-	+
speech comprehension- Token Test	-	-	+
repetition	-	-	-
<i>visuospatial function</i>			
Rey Complex Figure Test (CFT)	+	-	+
mazes	+	-	-
Block Design	-	+	-
Raven Coloured Matrices	-	-	+
<i>episodic memory and learning</i>			
Rey Auditory Verbal Learning Test (AVLT)	+	-	-
California Verbal Learning Test (CVLT)	+	+	-
Rey CFT	-	-	+
logical memory task	-	+	+
Family Pictures	-	+	-
<i>executive function</i>			
phonological / semantic fluency	+ / -	+ / -	+ / +
planning	-	-	-
cognitive flexibility- Wisconsin Card Sorting Test (WCST)	+	-	+
cognitive control- Stroop task	+	-	-
sequencing- Picture Arrangement	-	+	-
<i>praxis and motor coordination, motor speed</i>			
Trail Making Test A	+	+	-

Legend: WAIS-R, Wechsler Adult Intelligence Scale- Revised

planning abilities, which constitute a very important aspect of executive function. Moreover, to our knowledge, spontaneous speech and narrative writing trials have not been analyzed in the preclinical phase of FTDP-17. Therefore, in the case presented, both tests previously found to have good discriminative value and more extensive language and executive function evaluation were performed.

The present paper aims at showing the role of neuropsychological assessment in the early detection of FTDP-17. First, it reviews data from the literature on the assessment of FTDP-17 individuals in the preclinical phase. Then, we present

the case of an individual with P301L mutation who presented with slight abnormalities in neuropsychological assessment, though his social and occupational functioning was preserved.

## **MATERIAL AND METHODS**

### ***Case presentation***

The patient, a right-handed antique furniture restorer, was seen for the first time at the age of 48 and then again at age 49. He was referred for neurological and neuropsychological evaluation due to the family history of frontotemporal dementia (his father, 3 uncles and his grandmother seemed to be affected by this disease). Importantly, at the time of both evaluations neither the patient nor his wife reported any cognitive or behavioural abnormalities. The patient was still occupationally active.

Genetic testing on the patient's DNA, sequence analysis of *MAPT*, revealed a C to T missense mutation in exon 10, causing a proline-to-leucine change at codon 301 (P301L). This mutation has been shown to reduce the efficiency of microtubule binding, reducing the 4R tau isoform present in the soluble fraction.

At the age of 48 the neurological examination was normal, but neuropsychological evaluation identified subtle abnormalities (see Table 2). Magnetic resonance imaging (MRI) revealed atrophy of the frontal lobes and the vermis in the cerebellum.

A year later he developed symptoms of depression, attributed to external factors (mourning after his mother's death and preoccupation with the disease progression in his brother). Neurological examination revealed only a reduced arm swing on the right. MRI showed slightly deepened parietal sulci (and, to a lesser extent, the sulci of the frontal and temporal lobes) and slight diffuse subcortical and periventricular hyperintensities within white matter. Single Photon Emission Computerized Tomography (SPECT) revealed diffuse hypoperfusion within the whole brain (73-86% of cerebellar hypoperfusion) and focal hypoperfusion deficits (right temporo-occipital area-13%, left inferior prefrontal area-14% and left superior frontal area-21%).

## **NEUROPSYCHOLOGICAL TESTING**

As the two neuropsychological examinations were performed at different research centers by two neuropsychologists (AB and ES) and the data were retrospectively compared, the methodology of assessment was only partially consistent. The first rater used a clinical-experimental approach, while the second examiner used mostly a psychometric approach. However, at both examinations the neuropsychological assessment was very detailed and comprehensive.

Global cognitive status was assessed using the Mini-Mental State Examination (Folstein et al., 1975) and the Blessed Information, Memory and Concentration Scale (BIMC) (Blessed et al, 1968), and the Clock Drawing Test (CDT) (Sunderland et al., 1989); the BIMC and the CDT were administered only in the first assessment. The degree of daily dysfunction was rated using the Blessed Dementia

Rating (BDR) (Blessed et al, 1968) and the Clinical Dementia Rating (CDR) (Morris, 1993), supplemented by the Global Deterioration Scale (GDS) (Reisberg et al, 1992) in the first assessment. Semantic memory was assessed in the second examination using the Information subtest from the Polish adaptation of the Wechsler Adult Intelligence Scale-Revised (WAIS-R-PL) (Brzeziński et al., 2004). Abstract thinking was tested using the Similarities subtest of the WAIS-R-PL at both time points. Additionally, a classification task with 10 trials was administered at the first assessment (Łucki, 1995). In each trial the patient was shown 4 stimuli and asked to choose the odd one out, and then had to explain his choice. Language function was assessed using clinical probes in the first examination and with the Boston Naming Test (Kaplan et al., 1983), Token Test (deRenzi & Vignolo, 1982) and selected subscales from the Boston Diagnostic Aphasia Examination (Goodglass et al, 1983) in the second examination. Visuospatial function was rated by having the patient copy the Complex Figure Test (Rey, 1964; Lezak et al., 2004). Additionally, visual gnosis probes were administered in the first examination (masked and overlapping figures) (Łucki, 1995). Attention and working memory were assessed using the Digit Span from WAIS-R-PL (Brzeziński et al., 2004), the Trail Making Test (Kądziaława, 1990) and the letter / object cancellation trials (Halligan et al., 1991). The serial seven-subtraction task was administered at the first examination. Moreover, spatial working memory was tested using the Spatial Span trials (Pačhalska & Lipowska, 2007) and short-term visuospatial memory with the Benton Visual Retention Test (version F- recognition format) at the second examination (Lezak et al., 2004).

Verbal learning was assessed with a 10-word list learning task in the first examination and with the 15-word Auditory Verbal Learning Test (AVLT) (Choynowski & Kostro, 1980) in the second examination. Delayed spatial memory was tested with a delayed copy of the Rey / Taylor Complex Figure Test (CFT). In addition, logical memory (both immediate and delayed recall) was measured by means of story recall.

The Frontal Assessment Battery (FAB) (Dubois et al., 2000) was administered at both examinations as a screening measure of executive function. Verbal fluency trials assessed both semantic and phonemic fluency (the criteria are presented in Table 2). Planning was rated with the Tower of London (TOL) (Culbertson & Zillmer, 2005) in the first examination, and the Tower of Toronto (TOT) (Saint-Cyr et al., 1988) in the second examination. Additionally, to assess cognitive set-shifting and cognitive control, the Wisconsin Card Sorting Test (WCST) (Jaworska, 2002) and the Stroop Test (Stroop, 1935) were administered respectively at the second examination.

Motor coordination and praxis were tested at both examinations with efferent motor praxis trials (Łucki, 1995). Additionally, gesture and spatial praxis were assessed at the first examination, while the Finger Tapping Test (Kądziaława, 1990) and the Nine Hole Peg Test (Oxford et al., 2003) were administered at the second examination. The Digit Symbol subtest from the WAIS-R-PL (Brzeziński et al., 2004) was used as a measure of psychomotor speed in the second examination.

Table 2. Neuropsychological examination results

	Age (years/ months)	
	48/7	49/11
<b>Global cognitive status</b>		
Mini-Mental State Examination (max.30)	30	29
Blessed Information, Memory and Concentration Scale (max.37)	36	-
Blessed Dementia Rating Scale	0	0
Clinical Dementia Rating	0	0
<b>Semantic memory</b>		
WAIS-R Information (scaled score)	-	14
<b>Abstract thinking</b>		
WAIS-R Similarities (scaled score)	15	13
Classifications (odd one out) (max 10/10)*	10/10	-
<b>Language function</b>		
<i>Naming</i> - Boston Naming Test-BNT (max.60)	-	57
- 20 pictures (selected from BNT)	20	-
Speech comprehension- BDAE Commands (max. 15)	-	15
- Token Test (max. 168)	-	163
Repetition- BDAE high/low probability (max. 8)	-	7 / 8
Writing - BDAE Primer level dictation (max. 15)	-	15
- BDAE Writing to dictation (max. 10)	-	10
- BDAE Written confrontation naming (max. 10)	-	10
<b>Visuospatial Function</b>		
Rey/ Taylor Complex Figure Test (max. 36)	35	33
Visual gnosis - masked and overlapping figures (max.17)	16	-
<b>Attention/ Working memory</b>		
Digit Span forward (max. span)	5	6
Digit Span backwards (max. span)	5	4
Spatial Span forward (max. span)	-	6
Spatial Span backwards (max. span)	-	4
Benton Visual Retention Test-version F (max. 15)	-	13
Trail Making Test A- time in sec. /T score / errors	40 / 53T / 0	32 / 47T / 0
Trail Making Test B- time in sec. /T score / errors	65 / 48T / 0	63 /48T / 1
Mesulam's cancellation task- left/right (max. 30)	-	30 / 29
Behavioural Inattention Test- letter cancellation	-	no omissions
Letter cancellation task	3 omissions	-
Serial seven subtraction- errors	1/14	0/5
<b>Verbal learning</b>		
10-word list I-trial/X-trial/delayed recall/recognition	4/10/9/10	-
Logical memory - story recall (max.21/21)	10/15	-
Auditory Verbal Learning Test-learning curve	-	6,10,13,14,15
Auditory Verbal Learning Test -recognition	-	15
Auditory Verbal Learning Test -delayed recall in %	-	100%
Auditory Verbal Learning Test / 10-word list: intrusions	0	2
<b>Visuospatial memory</b>		
Rey / Taylor CFT after delay*	17	32

The patient's mood was clinically assessed in the first examination, while in the second examination it was also psychometrically rated by means of the Beck Depression Inventory (BDI) (Beck et al., 1961).

## RESULTS

### *Baseline neuropsychological assessment*

Baseline neuropsychological examination revealed only subtle deficits. General cognitive status and occupational activity were intact. The patient did not re-

Table 2. Neuropsychological examination results (cont.)

<b>Executive function</b>		
screening- Frontal Assessment Battery (max. 18)	18	18
verbal fluency		
-semantic: supermarket / animals / plants (60 sec.)	- / 17 / -	23 / 26 / 22
fruit and vegetables (60 sec.)	16	-
-phonological: „K” / „O” / “P” / “W” / “S” (60 sec.)	- / - / 6 / 7 / -	7 / 6 / 11 / - / 12
planning		
Tower of London – total correct score (standardized score)	106	-
Tower of London – total move score (standardized score)	112	-
Tower of London – problem solving time (standardized score)	116	-
Tower of London – rule violation (standardized score)	104	-
Tower of Toronto – total score	-	11
Tower of Toronto – rule violation	-	2
mental set-shifting		
Wisconsin Card Sorting Test- categories completed	-	6
errors- standardized score	-	110
cognitive control		
Stroop task- errors in the interference trial	-	1 (corrected)
<b>Motor coordination, praxis and dexterity</b>		
WAIS-R Digit Symbol (scaled score)	-	11
efferent motor praxis – I trial / II trial (max. 5)	5 / 5	5 / 5
Finger Tapping Test – left hand/ right hand	-	72T / 68 T
Nine Hole Peg test – left hand / right hand	-	19 sec. / 15 sec.
Reciprocal coordination (max.10)	10	-
Gesture praxis (max.5)	4	-
Spatial praxis (max.6)	5	-
<b>Mood</b>		
Beck Depression Inventory	-	2

Legend: BDAE, Boston Diagnostic Aphasia Examination; WAIS-R, Wechsler Adult Intelligence Scale- Revised;

\*30 min. delay in the first examination and 3 min. delay in the follow-up assessment

port any cognitive complaints, and screening methods (GDS, CDT, MMSE, FAB and CDR) failed to show any abnormalities. General orientation, abstract thinking, verbal learning and delayed recall (both verbal and visual) were preserved. Information processing was normal. Nevertheless, deficits in attention were observed in serial seven subtraction and the letter cancelation task (3 omissions). The assessment of language function revealed good naming and comprehension, no prosody dysfunctions, and proper discourse with intact grammar. Visuospatial function seemed preserved despite two omission errors (in the visual gnosis task and the Rey CFT; see Figure 1) that were probably due to attention deficits. As mentioned above, delayed verbal memory was intact, but immediate verbal and visual memory was impaired. Executive functions were also disturbed, which was mostly evident in verbal fluency trials, assessing the initiation and flexibility of the search and retrieval process. Phonemic fluency was markedly decreased in comparison to semantic fluency. Moreover, perseverations and repetitions were present. Planning ability, measured with the Tower of London Task (Culbertson & Zillmer, 2005), was above normal range, with no rule violations. Motor learning and reciprocal coordination were intact. No praxis deficits or motor slowing were identified. The patient’s mood and behavior were normal.



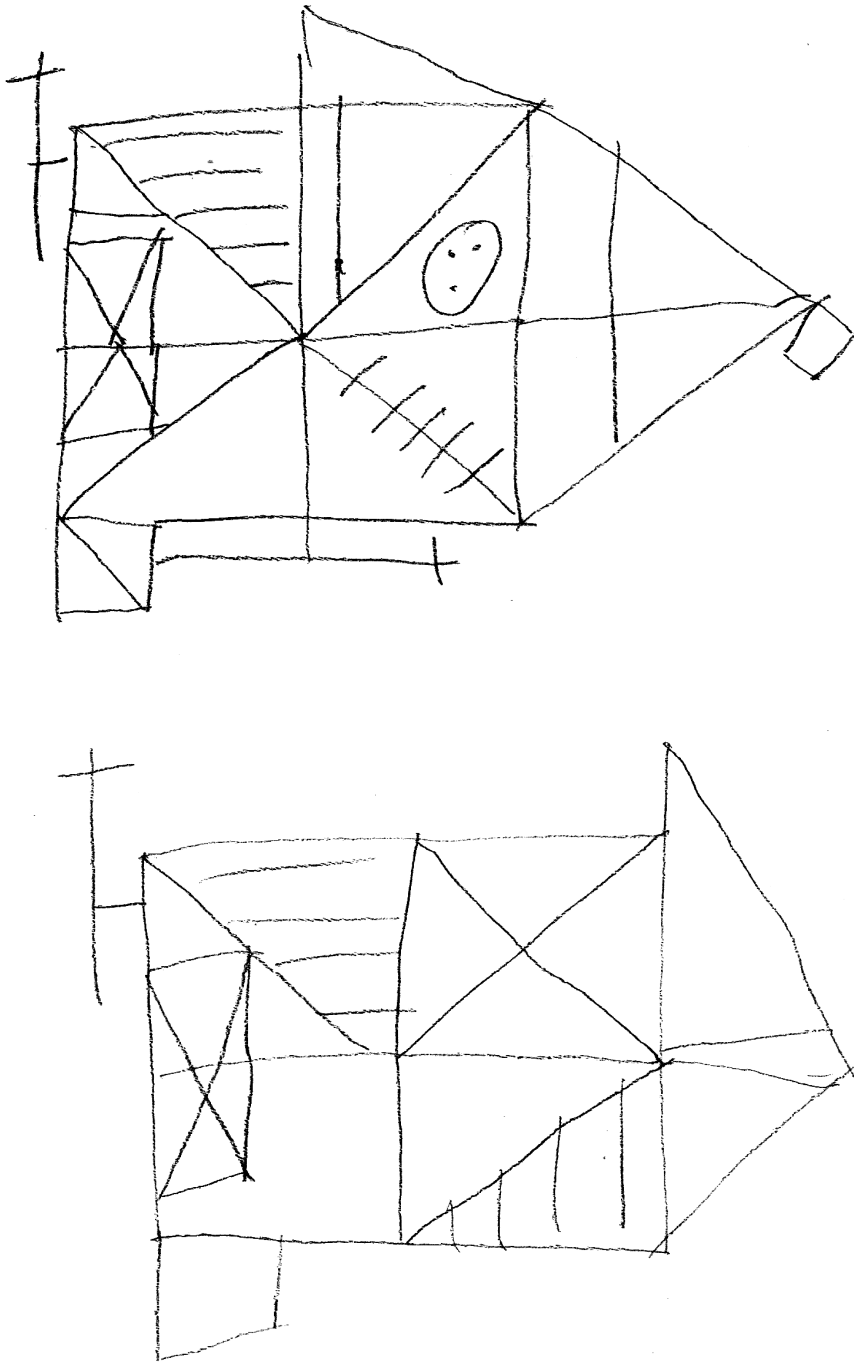


Fig. 1. Rey Complex Figure Test at the age of 48:a) copy, b) delayed recall (30 min.)

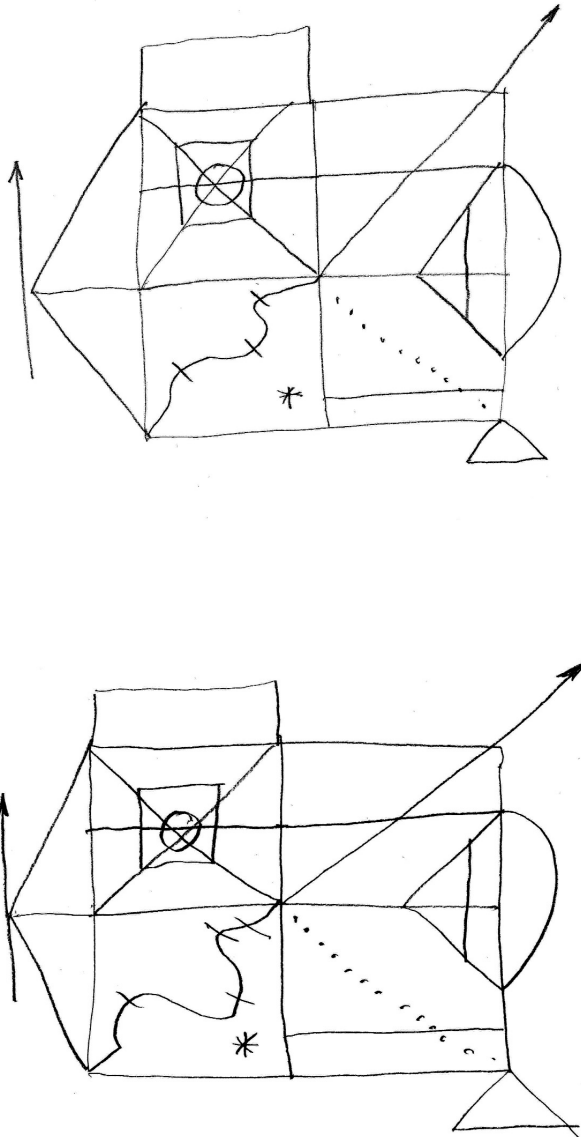


Fig. 2. Taylor Complex Figure Test at the age of 49: a) copy, b) delayed recall (3 min.)

***Follow-up neuropsychological assessment***

At follow-up, the patient's global cognitive status and occupational performance were still within the normal range. Abstract thinking, semantic memory and visuospatial function were preserved. Testing for unilateral neglect did not reveal any abnormalities.

Nevertheless, while describing the Cookie Theft picture from the BDAE, the patient's phrases seemed shortened and simplified with slight agrammatism (see Appendix). His prosody was rather monotonous, but no formal evaluation of prosody or dysarthria was performed. Naming and speech comprehension were within normal limits. Repetition was mostly preserved. Writing to dictation was preserved, but written picture description (from FAST) evidenced not only shortened and simplified phrases, but also phonological difficulties (see Appendix). Slight language alterations (phonological and syntactic) occurred only occasionally. Decreased phonemic fluency and intrusions in verbal learning trials also seemed suggestive of language impairment.

In working memory, both the phonological loop and visuospatial sketchpad were slightly impaired. Verbal learning and visuospatial memory were within normal limits. The intrusions observed in AVLT (at the beginning and not in the delayed recall trial) could be linked to language impairment. One of the intrusions was both phonologically and semantically related to one of the target words. The other was unrelated to the list. This may reflect progressive language impairment, as intrusions were absent in the first neuropsychological examination.

Executive function seemed to be preserved at screening assessment (FAB). Mental set-shifting and cognitive control were at the normal level. However, planning ability seemed to be affected. For example, since the planning task- Tower of Toronto- requires procedural memory involvement and visuospatial reasoning, it seems to be of diagnostic significance, taking into account the patient's profession (furniture restoration). What is more, phonemic fluency was very deficient in comparison to semantic fluency. After retrieving a couple of words during the first phonemic fluency trial, the patient started to name objects from the examination room (starting with the target letter). There were no repetition or intrusion errors. No errors were noted in copying Luria's alternate design or multiple loops. However, in the AVLT, the patient tried to recall words in a fixed order despite the repetition of the instructions to ignore the order of words. Moreover, there were perseverations of elements in Taylor's CFT that cannot be explained by visuospatial difficulties (see: Figure 2).

Motor coordination was preserved in both hands. Questionnaire assessment of the patient's mood did not indicate a depressive mood. The patient seemed rather apathetic than depressed. In comparison with the first assessment, there was a slight deterioration in language function and planning. Other aspects of cognitive function remained unchanged.

## **DISCUSSION**

Decreased phonemic fluency and motor speech abnormalities are among the earliest signs of FTDP-17 (Ferman et al., 2003; Liss et al., 2006). In the present paper we describe a patient with FTDP-17 who, albeit with no neurological signs, developed subtle neuropsychological and psychiatric abnormalities. In particular, confirming previous reports from the literature (Alberici et al., 2004; Geschwind

et al., 2001; Ferman et al., 2003), this patient's phonemic fluency seemed to be predominantly affected early in the course of the disease. Importantly, this is the first paper documenting early neuropsychological changes in a Polish patient with FTDP-17. The first Polish family with FTDP-17 has recently been reported (Narożańska et al., 2011). A genetic analysis is now being conducted in order to verify if our patient belongs to the same family.

The present report focuses on executive and language function assessment in the context of comprehensive neuropsychological testing results. A striking asymmetry was noted between phonemic and semantic fluency results at both assessments. Higher semantic fluency scores than phonemic fluency scores are typical for healthy individuals. However, the magnitude of this discrepancy observed in our patient (up to 20 exemplars per minute difference) and its stability across trials (three semantic trials and four phonemic trials in the follow-up examination) proves that the phonemic fluency deficit is of clinical importance and cannot be explained by psychomotor slowing or depressed mood (as indicated by much higher semantic fluency scores and clinical observation) (Henry & Crawford, 2005). Phonemic fluency was deficient even at the first assessment, despite normal cognitive flexibility and cognitive control at that time.

Both phonemic and semantic fluency rely on working memory. However, phonemic fluency is more closely related to the phonological loop, while semantic fluency relies more on the visuospatial sketchpad (Rende, Ramsberger & Miyake, 2002). In the light of such data, deficient phonemic fluency in our patient could be regarded as the consequence of phonological loop impairment. Nonetheless, the patient committed only one phonological error in writing, no repetition errors were noted in the fluency trials, and no other data from language assessment (preserved spontaneous speech, naming, reading and repetition; qualitative analysis of verbal fluency trials-lack of repetition errors) seem to support this hypothesis. However, the agrammatism that appeared in the oral picture description may indicate early signs of language deficit. Moreover, the left prefrontal hypoperfusion, observed in the patient may tip the scales in favor of a language rather than executive basis of impairment. Phonemic fluency probes can also be regarded as a measure of productivity that is likely to be impaired in disorders affecting the frontal lobes (Lezak, Howieson & Loring, 2004), such as FTDP-17. However, in our case diminished phonemic fluency is not associated with poor recall in AVLT. Moreover, the analysis of performance in Tower of Toronto does not prove generalized problems with initiation of problem solving, as the 3-move problem was correctly performed in the first trial and the first trial from the 4-move condition was quite well performed. Taking into account the aforementioned data, a language deficit is likely to underlie poor phonemic fluency. Since FTDP-17 usually affects both language and executive function, tasks such as verbal fluency probes may reflect aphasia and/or dysexecutive syndrome, and their processual interpretation is difficult.

In the context of the differential neuropsychological diagnosis of dementia the analysis of discrepancy between semantic and phonemic fluency is very impor-

tant. In primary progressive aphasia (PPA) and in subcortical dementias (such as Parkinson's disease dementia) phonemic fluency is lower than semantic fluency. On the other hand, in semantic dementia or Alzheimer's disease the reverse pattern of results is noted (Marczinski & Kertesz, 2006). In subcortical dementias poor phonemic fluency is regarded as the consequence of impaired initiation and mental flexibility (poor search strategy- clustering and switching) (Duke & Kaszniak, 2000), while in PPA it is believed to reflect phonological impairment (Marczinski & Kertesz, 2006). FTDP-17, as an overlapping syndrome, encompasses both some characteristic features of subcortical dementias (such as decreased initiative and productivity) and of PPA (mainly impoverished spontaneous speech eventually leading to mutism).

In our patient, language assessment identified mild deficits, both phonological (in writing) and syntactic (in the oral verbal output). Verbal output seemed slightly impoverished. When the patient's speech is compared to the language profiles of progressive aphasia, it resembles non-fluent primary progressive aphasia. However, anomia, the hallmark of aphasia, is not present in our patient. What is more, the analysis of speech of patients with more advanced FTDP-17 shows that the impoverished speech in FTDP-17 is more closely related to diminished productivity than to anomia (Sitek et al., 2010).

Planning was initially preserved but declined mildly over time in our patient. However, different measures of planning ability were used, which hinders direct comparison. Perseveration errors in copying the complex figure emerged in the second examination, which may indicate the deterioration of executive function.

Slight planning problems and language abnormalities (phonological errors and slightly impoverished oral and written verbal output, possible slight agrammatism), observed in the second examination, have not previously been reported in individuals with intact occupational and social function. However, all these deficits were subsequent to the phonemic fluency deficit. An early phonemic fluency deficit in FTDP-17 can be regarded as a sign of executive impairment, but may also be linked to language decline. As documented by our data, deficient phonemic fluency may precede subsequent aphasic errors.

At follow-up, motor speech abnormalities were observed, e.g. reduced prosody. Liss et al. (2006) reported motor speech changes as a harbinger of the disease. However, no objective assessment of prosody was performed in our study to confirm the clinical observation.

Our report highlights the need for qualitative analysis of test performance to detect neuropsychological abnormalities in presymptomatic patients with FTDP-17. For example, at baseline, attentional errors were detected in visuospatial and praxis trials. In the 2nd assessment, intrusions emerged in the AVLT that, in light of the preserved delayed recall and perseverated details in copying the CFT, clearly demonstrated executive and language deficits not evidenced in the quantitative analysis. Importantly, depression cannot account for the pattern of results seen in our patient, since the learning rate was not slowed, semantic fluency was preserved, and working memory was not significantly impaired. Also, phonological

difficulties and agrammatism do not occur in depression (Porter, Bourke & Gallagher, 2002; Douglas & Porter, 2009). By comparison, in depression semantic fluency is significantly impaired (Henry & Crawford, 2005), which was not the case in our patient.

The clinical presentation of frontotemporal syndromes is related to the specific patterns of hypometabolism, with frontal hypometabolism being associated with behavioural variant of FTD, temporal with semantic dementia (SD), and left perisylvian with progressive nonfluent aphasia (PNFA). The predominant executive dysfunction and slight language impairment in our patient is consistent with the mostly left-sided frontal hypoperfusion evidenced by SPECT. The relative sparing of the medial temporal lobes, the most severe atrophy involving the lateral part of the anterior temporal lobes, and early frontal lobes loss are features of P301L *MAPT* mutation, which is rapidly progressive (Whitwell, 2009). The atrophy of the anterior temporal lobes explains the poor performance in naming, which could be an overlap syndrome with primary progressive aphasia, but the behavioral changes that emerge early in this mutation help to confirm the diagnosis.

The most important shortcoming of our study is that different sets of tests and clinical probes were used at baseline and follow-up. Moreover, none of the assessments contained objective measures of prosody, and the motor aspect of speech was not analyzed. Nonetheless, the comparison between the two assessments clearly shows that a comprehensive examination, regardless of the proposed approach (psychometric or clinical-experimental), provides meaningful data on the subtle neuropsychological deficits in early FTDP-17. Our case report also indicates that simple screening measures of general cognition (e.g. MMSE) or even screening tools aimed specifically at executive dysfunction (e.g. FAB) may not be sensitive enough to detect the early and relatively mild neuropsychological problems in FTDP-17, which, if not assessed qualitatively, might be easily missed or overlooked. In most cases of patients diagnosed with one FTD variant, later in the disease course symptoms characteristic for the other variant also develop, e.g. a patient with PNFA may be later diagnosed with corticobasal degeneration (Kertesz & Munoz, 2003). This report shows that FTDP-17 may be an overlap syndrome even at the early stages of the disease, sharing clinical and neuroimaging characteristics of the frontal variant of FTD and PNFA. Future group studies are warranted, however, to better understand the neuropsychological deficits associated with FTDP-17.

## **ACKNOWLEDGEMENTS**

This study was supported by a grant entitled "The role of neuropsychological assessment, smell identification testing and neuroimaging in the detection of early symptoms of FTDP-17," GI-836, funded by the Polish Ministry of Science and Higher Education. EJS was supported by a START Scholarship from the Foundation for Polish Science. The authors are very grateful to Dr Michal Harciarek from the University of Gdansk (Poland) for his inspiring comments and discussion of the results.

## REFERENCES

- Alberici, A., Gobbo, C., Panzacchi, A. et al. (2004). Frontotemporal dementia: impact of P301L tau mutation on a healthy carrier. *Journal of Neurology, Neurosurgery and Psychiatry*, *75*, 1607-1610.
- Arvanitakis, Z., Witte, R.J., Dickson, D.W., Tsuboi, Y., Uitti, R.J., Slowinski, J., Hutton, M.L., Lin, S.C., Boeve, B.F., Cheshire, W.P., Pooley, R.A., Liss, J.M., Caviness, J.N., Strongosky, A.J. & Wszolek, Z.K. (2007). Clinical-pathologic study of biomarkers in FTDP-17 (PPND family with N279K tau mutation). *Parkinsonism & Related Disorders*, *13*, 230-239.
- Beck, A.T., Ward, C.H., Mendelson, M., Mock, J. & Erbaugh, J. (1961). An inventory for measuring depression. *Archives of General Psychiatry*, *4*, 561-571.
- Blessed, G., Tomlinson, B.E. & Roth, M. (1968). The association between quantitative measures of dementia and of senile change in the cerebral grey matter of elderly subjects. *British Journal of Psychiatry*, *114*, 797-811.
- Boeve, B.F. & Hutton, M. (2008). Refining Frontotemporal Dementia With Parkinsonism Linked to Chromosome 17: Introducing FTDP-17 (*MAPT*) and FTDP-17 (*PGRN*). *Archives of Neurology*, *65*, 460-464.
- Brzezinski, J., Gaul, M., Hornowska, E., Jaworowska, A., Machowski, A. & Zakrzewska, M. (2004). *Skala Inteligencji dla Dorosłych Wechslera. WAIS-R(PL) – podręcznik*. Warsaw, Poland: Pracownia Testów Psychologicznych. (in Polish).
- Choynowski, M. & Kostro, B. (1980). *Podręcznik do testu 15 słów Rey'a*. Warsaw, Poland: PWN Press. (in Polish).
- Culbertson, W.C. & Zillmer, E.A. (2005). *Tower of London – Drexler University (TOL DX): Second Edition. Technical Manual*. New York: Multi-Health System.
- DeRenzi, E. & Vignolo, L.A. (1962). The Token Test: a sensitive test to detect receptive disturbances in aphasics. *Brain*, *85*, 665-678.
- Douglas, K.M. & Porter, R.J. (2009). Longitudinal assessment of neuropsychological function in major depression. *Australian & New Zealand Journal of Psychiatry*, *43*, 1105-1117.
- Dubois, A., Slachevsky, A., Litvan, I. & Pillon, B. (2000). The FAB -A frontal assessment battery at bedside. *Neurology*, *55*, 1621-1626.
- Duke, L.M. & Kaszniak, A.W. (2000). Executive control functions in degenerative dementias: a comparative review. *Neuropsychology Review*, *10*, 75-99.
- Ferman, T.J., McRae, C.A., Arvanitakis, Z., Tsuboi, Y., Vo, A. & Wszolek, Z.K. (2003). Early and pre-symptomatic neuropsychological dysfunction in the PPND family with the N279K tau mutation. *Parkinsonism & Related Disorders*, *9*, 265-270.
- Folstein, M.F., Folstein, S.E. & McHugh, P.R. (1975). Mini-mental state. *Journal of Psychiatry Research*, *12*, 189-198.
- Foster, N.L., Wilhelmsen, K., Sima, A.A., Jones, M.Z., D'Amato, C.J. & Gilman, S. (1997). Frontotemporal dementia and parkinsonism linked to chromosome 17: a consensus conference. *Annals of Neurology*, *41*, 706-715.
- Geschwind, D.H., Robidoux, J., Alarcon, M., Miller, B.L., Wilhelmsen, K.C., Cummings, J.L. & Nasreddine, Z.S. (2001). Dementia and neurodevelopmental predisposition: cognitive dysfunction in presymptomatic subjects precedes dementia by decades in frontotemporal dementia. *Annals of Neurology*, *50*, 741-746.
- Goodglass, H. & Kaplan, E. (1983). *Boston Diagnostic Aphasia Examination (BDAE)*. Philadelphia: Lea and Febiger. Distributed by Psychological Assessment Resources, Odessa, FL.
- Halligan, P.W., Cockburn, J. & Wilson, B.A. (1991). The behavioural assessment of visual neglect. *Neuropsychological Rehabilitation*, *1*, 5-32.
- Henry, J. & Crawford, J.R. (2005). A meta-analytic review of verbal fluency deficits in depression. *Journal of Clinical & Experimental Neuropsychology*, *27*, 78-101.
- Jaworowska, A. (2002). *Test Sortowania kart z Wisconsin (WCST) – podręcznik*. Warsaw: Pracownia Testów Psychologicznych. (in Polish).
- Kadzielawa, D. (ed.). (1990). *Podręcznik do baterii testów neuropsychologicznych Halsteada-Reitana*. Warsaw: Pracownia Testów Psychologicznych. (in Polish).

- Kaplan, E.F., Goodglass, H. & Weintraub, S. (1983). *The Boston Naming Test*. 2nd ed. Philadelphia: Lea and Febiger.
- Kelley, B.J., Haidar, W., Boeve, B.F., Baker, M., Graff-Radford, N.R., Krefft, T., Frank, A.R., Jack, C.R. Jr., Shiung, M., Knopman, D.S., Josephs, K.A., Parashos, S.A., Rademakers, R., Hutton, M., Pickering-Brown, S., Adamson, J., Kuntz, K.M., Dickson, D.W., Parisi, J.E., Smith, G.E., Ivnik, R.J. & Petersen, R.C. (2009). Prominent phenotypic variability associated with mutations in Progranulin. *Neurobiology of Aging*, 30, 739-751.
- Kertesz, A. & Munoz, D.G. (2003). Primary progressive aphasia and Pick complex. *Journal of the Neurological Sciences*, 206, 97-107.
- Lezak, M.D., Howieson, D.B. & Loring, D.W. (2004). *Neuropsychological assessment*. 4th ed. New York, Oxford: Oxford University Press.
- Liss, J.M., Krein-Jones, K., Wszolek, Z.K. & Caviness, J.N. (2006). Speech characteristics of patients with pallido-ponto-nigral degeneration and their application to presymptomatic detection in at-risk relatives. *American Journal of Speech-Language Pathology*, 153, 226-235.
- Łucki, W. (1995). *Zestaw prób do badania procesów poznawczych u pacjentów z uszkodzeniami mózgu-podręcznik*. Warsaw: Pracownia Testów Psychologicznych Polskiego Towarzystwa Psychologicznego.
- Marczinski, C.A. & Kertesz, A. (2006). Category and letter fluency in semantic dementia, primary progressive aphasia, and Alzheimer's disease. *Brain & Language*, 97, 258-265.
- McRae, C.A., Diem, G., Yamazaki, T.G., Mitek, A., Wszolek, Z.K. (2001). Interest in genetic testing in pallido-ponto-nigral degeneration (PPND): a family with frontotemporal dementia with parkinsonism linked to chromosome 17. *European Journal of Neurology*, 82, 179-183.
- Morris, J. (1993). Clinical Dementia Rating (CDR): current version and scoring rules. *Neurology*, 43, 2412-2414.
- Narożańska, E., Jasińska-Myga, B., Sitek, E.J., Robowski, P., Brockhuis, B., Lass, P., Dubaniewicz, M., Wiczorek, D., Baker, M., Rademakers, R., Wszolek, Z.K. & Sławek, J. (2011). Frontotemporal dementia and parkinsonism linked to chromosome 17 – the first Polish family. *European Journal of Neurology*, 18, 535-537.
- Oxford Grice, K., Vogel, K.A., Le, V., Mitchell, A., Muniz, S. & Vollmer, M.A. (2003). Adult norms for a commercially available Nine Hole Peg Test for finger dexterity. *American Journal of Occupational Therapy*, 57, 570-573.
- Pąchalska, M. & Lipowska, M. (2007). *Skala Badania Pamięci Wechslera- III (Wechsler Memory Scale, WMS-III)*. Kraków: Fundacja na Rzecz Osób z Dysfunkcjami Mózgu.
- Porter, R.J., Bourke, C. & Gallagher, P. (2007). Neuropsychological impairment in major depression: its nature, origin and clinical significance. *Australian & New Zealand Journal of Psychiatry*, 41, 115-128.
- Reisberg, B., Ferris, S.H., de Leon, M.J. & Crook, T. (1982). The global deterioration scale for assessment of primary degenerative dementia. *American Journal of Psychiatry*, 139, 1136-1139.
- Rende, B., Ramsberger, G. & Miyake, A. (2002). Commonalities and differences in the working memory components underlying letter and category fluency tasks: a dual-task investigation. *Neuropsychology*, 16, 309-321.
- Rey, A. (1964). *L'examen clinique en psychologie*. Paris: Presses Universitaires de France.
- Saint-Cyr, J.A., Taylor, A.E. & Lang, A.E. (1988). Procedural learning and neostriatal dysfunction in man. *Brain*, 111, 941-959.
- Sitek, E., Narożańska, E., Sławek, J., Wiczorek, D., Brockhuis, B., Lass, P., Dubaniewicz, M., Jasińska-Myga, B., Baker, M., Rademakers, R., Wszolek, Z.K. (2009). Unilateral neglect in a patient diagnosed with frontotemporal dementia and parkinsonism linked to chromosome 17. *Acta Neuropsychiatrica*, 21, 209-210.
- Sitek, E.J., Narożańska, E., Sławek, J., Wójcik, J., Wiczorek, D., Robowski, P., Schinwelski, M., Jasińska-Myga, B., Baker, M., Rademakers, R. & Wszolek, Z.K. (2010). Psychometric evaluation of personality in a patient with FTDP-17. *Psychiatry and Clinical Neurosciences*, 64, 211-212.
- Sitek, E.J., Narożańska, E., Wiczorek, D., Brockhuis, B., Lass, P. & Sławek, J. (2010). Afazja pierwotna postępująca z zachowaną płynnością mowy – specyfika diagnozy neurologicznej i neu-



ropsychologicznej. In: M Paćhalska & G Kwiatkowska (eds.) *Neuropsychologia a humanistyka* (pp.125-134). Lublin: Wyd. UMCS.

Stroop, J.R. (1935). Studies on interference in serial verbal reactions. *Journal of Experimental Psychology*, 28, 643-662.

Sunderland, T., Hill, J., Mellow, A., Lawlor, B., Gundersheime, J., Newhouse, P. & Grafman, J. (1989). Clock drawing in Alzheimer's Disease: a novel measure of dementia severity. *Journal of the American Geriatrics Society*, 37, 725-729.

Whitwell, J.L., Jack, C.R., Boeve, B.F., Senjem, M.L., Baker, M., Rademakers, R., Ivnik, R.J., Knopman, D.S., Wszolek, Z.K., Petersen, R.C. & Josephs, K.A. (2009). Voxel-based morphometry patterns of atrophy in FTLD with mutations in *MAPT* or *PGRN*. *Neurology*, 72, 813–820.

**Address for correspondence:**

Emilia Sitek

Department of Neurology

St. Adalbert Hospital

Jana Pawla II 50

80-462 Gdansk

POLAND

e-mail:emsitek@gmail.com

## APPENDIX

### 1. Oral picture description: Cookie theft from BDAE

*Translation:* [What's happening in the picture?]\* So..happ..The picture is happening in the kitchen. A house and a footpath can be seen by the window. Mum is standing by the sink, which is overflowing. She is drying the dishes. There are cups and plates on the top (of the kitchen cabinet). It is happening on the right side of the kitchen. On the left side – daughter with son. Daughter is standing on the floor. Son, a boy has gone up the stool, which is falling down. He got into a (kitchen) cabinet so as to reach the cookies. Sister is holding out her hand to make him give her a cookie as well. (48 sec.) [Is that all?]. Yes, that's all.

Original version in Polish: [Co się tutaj dzieje?] Więc...dzie...Obrazek dzieje się w kuchni. Za oknem widać jakiś domek, ścieżkę. Mama stoi przy zlewie, z którego przelewa się woda. Wyciera naczynia. Na blacie stoją filiżanki i talerz. Dzieje się to po prawej stronie kuchni. Z lewej strony - córka z synem. Córka stoi na podłodze. Syn, chłopiec, wszedł na stół, który się przewraca. Wszedł do szafki, żeby sięgnąć ciastka. Siostra ma wyciągniętą rękę, żeby podała jej też ciastko." (48 sek. ) [Wszystko?] Wszystko."

\*examiner's intrusions in square brackets

### 2. Written picture description from FAST

*Translation:* A man is walking with a dog at the quay. A fishing boat is sailing is with a helmsman. A canoeist is sailing nearby (phonological error, perseveration – "oboko" instead of "obok"). A sailing boat is moored at the quay. The boys are standing on the bridge and feeding the ducks, which are swimming in the river. There are trees and the school on the opposite side of the river. There are hills behind them.

Original version in Polish: Nabrzeżem spaceruje człowiek z psem. Rzeką płynie barka ze sternikiem. Oboko (phonological error, the correct word is „obok”) płynie kajakarz. Przy nabrzeżu jest zacumowana żaglówka. Na moście stoją chłopcy i karmią kaczki, które pływają w rzece. Po drugiej stronie rzeki są drzewa i budynek szkoły. Za nimi są wzniesienia.