

Received: 11.06.2015
Accepted: 28.12.2015

A – Study Design
B – Data Collection
C – Statistical Analysis
D – Data Interpretation
E – Manuscript Preparation
F – Literature Search
G – Funds Collection

DOI:10.5604/17307503.1193815

BRAIN ACTIVITY RELATED TO THE CONGRUENT AND INCONGRUENT PART OF THE STROOP TEST PERFORMANCE-NOT ONLY DIFFERENCES BUT ALSO SIMILARITIES IN THE BRAIN ACTIVITY PATTERN. A NEUROIMAGING PET(H₂O₁₅) STUDY

Anita Markowska^{1(A,B,C,D,E,F)}, Bogdan Małkowski^{2,3(A,B,C,D,E,F)},
Marek Wróbel^{2(A,B,C,D,E,F)}, Marcin Ziółkowski^{1(A,B,C,D,E,F)}

¹ Department of Psychiatry Nursing, Collegium Medicum, Nicolaus Copernicus University in Toruń, Poland

² Oncology Centre Prof F. Łukaszczyk Memorial Hospital, Bydgoszcz, Poland

³ Department of Nuclear Medicine, Collegium Medicum, Nicolaus Copernicus University in Toruń, Poland

SUMMARY

Background:

Previous studies on brain activity during the completion of the Stroop test focused mainly on finding differences between brain activity during the completion of the congruent and incongruent parts of the test. Based on the results of those studies, the key role of the DLPFC and the ACC was emphasized in solving the cognitive conflict accompanying the completion of the incongruent part of the Stroop task. Less attention was paid to other areas of the brain that form a neurofunctional system involved in the Stroop task. The aim of the study was to examine brain activity during the completion of the non-interferential and interferential parts of the Stroop test.

Material/ Methods:

Colour-word congruent (A), incongruent (B), and baseline (C) conditions were presented in two ABC trials to 18 healthy, right-handed study participants during 8 H₂O₁₅ PET scans. SPM8 (*Statistical Parametric Mapping* – <http://www.fil.ion.ucl.ac.uk/spm/>) was used for a voxel-by-voxel analysis of the neuroimaging data.

Results:

Both A and B task performances are related to increased activity in the area of the frontal lobes (the inferior frontal gyrus on both sides and the right dorsolateral prefrontal cortex), areas of the medial prefrontal cortex (including the cingulate gyrus), some areas of the occipital lobes, and the temporal lobes, including the insula. We can also observe some subcortical activation of thalamic and cerebellar structures.

Conclusions:

A similar activity pattern for most brain areas occurs during the non-interferential and interferential parts of the Stroop test. In addition to the prefrontal areas, which have so far been of the greatest interest for researchers in terms of their significance in solving a cognitive conflict, other cortical and subcortical areas are involved in the completion of the Stroop test. Therefore, it can be concluded that structural damage to or dysfunction of any of them affects performance in the Stroop test.

Key words: interference effect, cognitive conflict, prefrontal cortex, cognitive inhibition

INTRODUCTION

The Stroop test (Stroop, 1935) is a method for modelling a situation of cognitive conflict, which is why it is used in studies of neural correlates of executive attention as a cognitive control mechanism (Posner & Petersen, 1990). During the Stroop test, participants are asked to name the colour of the font in a situation when it is consistent with the meaning of the word (e.g., the word “yellow” is written in yellow) and when the font colour is inconsistent with the meaning of the word (e.g., the word “yellow” is written in green). The most important phenomenon that occurs during the Stroop test is the effect of interference (Stroop, 1935; McLeod, 1991), which consists of a prolonged reaction when a participant is asked to name the colour of the font that is incompatible with the meaning of the word. Stroop (1935) explained the effect of interference with the need to repress the automated, perfectly-learned reaction to the meaning of the word. This fixed reaction makes it difficult to choose a correct response to a new criterion, creating a situation referred to in the literature as a situation of cognitive conflict.

The first results indicating the neural correlates of the Stroop test were obtained in studies on people with lesions to the lateral prefrontal cortex of the right (Vendrell et al., 1995) and left (Perret, 1974) cerebral hemispheres. As technology advances, new opportunities for a more thorough examination of the CNS have appeared. The current knowledge of the brain mechanisms underlying the completion of the Stroop test and the effect of interference is based on data obtained in studies using the following methods: PET – positron emission tomography (Pardo et al., 1990; Bench et al., 1993; George et al., 1994; Carter et al., 1995; Taylor et al., 1997), fMRI – functional magnetic resonance imaging (Bush et al., 1998; Peterson et al., 1999; Carter et al., 2000; Leung et al., 2000; Banich et al., 2000; MacDonald et al., 2000; Milham et al., 2001; Zysset et al., 2001; Gruber et al., 2002; Milham et al., 2003), and MEG – magnetoencephalography (Ukai et al., 2002).

The majority of the results of the aforementioned studies (Pardo et al., 1990; Bench et al., 1993; George et al., 1994; Carter et al., 1995; Bush et al., 1998; Peterson et al., 1999; Carter et al., 2000; Leung et al., 2000; MacDonald et al., 2000; Milham et al., 2001; Gruber et al., 2002; Milham et al., 2003), but not all of them (Taylor et al., 1997; Banich et al., 2000; Zysset et al., 2001; Ukai et al., 2002), emphasize that the interference effect is strongly associated with the increased activity of the anterior cingulate cortex (ACC). The literature also describes an extensive involvement of the prefrontal areas in the completion of the Stroop test. Most researchers stress here the important role of the dorsolateral prefrontal cortex (DLPFC) (George et al., 1994; Bush et al., 1998; Peterson et al., 1999; Banich et al., 2000; MacDonald et al., 2000; Milham et al., 2001; Zysset et al., 2001; Ukai et al., 2001; Milham et al., 2003), although there is also data that indicates the activity of the frontal areas of the prefrontal cortex (aPFC) (Bench et al., 1993; Carter et al., 1995; Zysset et al., 2001; Ukai et al., 2002) and the ventrolateral prefrontal cortex (VLPFC) (Leung et al., 2000; Taylor et al., 1997; Banich et al., 2000; Milham et al., 2001; Zysset et al., 2001). Other areas that are involved

in solving the Stroop task according to study results are the (pre)motor cortex (Pardo et al., 1990; Bush et al., 1998; Leung et al., 2000; Ukai et al. 2001), parietal areas (Bench et al., 1993; Carter et al., 1995; George et al., 1994; Bush et al., 1998; Peterson et al., 1999; Milham et al., 2001; Zysset et al. 2001; Ukai et al., 2001.), temporal areas (Pardo et al., 1990; Bush et al., 1998; Peterson et al., 1999; Leung et al., 2000; Zysset et al., 2001; Milham et al., 2003), occipital areas (Pardo et al., 1990; Carter et al., 1995; George et al., 1994; Taylor et al., 1997), the insular cortex (Carter et al., 1995; George et al., 1994; Leung et al., 2000), and subcortical areas, i.e., the striatum (Pardo et al., 1990; George et al., 1994; Peterson et al., 1999) and the thalamus (Carter et al., 1995; George et al., 1994; Peterson et al., 1999; Leung et al., 2000).

A meta-analysis of the results of PET and fMRI neuroimaging examinations conducted between 1990 and 2005 (Nee et al., 2007) indicates that two large active areas in the left hemisphere are associated with the Stroop task. These are the left dorsolateral prefrontal cortex (DLPFC), which extends towards the inferior areas down to the insular cortex, and the medial frontal cortex, including the anterior cingulate cortex (ACC), also of the left hemisphere. A cluster in the posterior area of the left parietal cortex is also noteworthy. In the right hemisphere, the areas associated with the Stroop test are the dorsolateral prefrontal cortex and posterior areas of the cortex. However, these areas are not as extensive as in the case of the aforementioned areas of the left hemisphere. The results of the meta-analysis also indicate the activity of the thalamus during the Stroop test. The above neuroimaging data shows that the areas of the ACC and the DLPFC should be considered important elements of larger neurofunctional systems forming circuits, along with subcortical areas including the thalamus and the basal ganglia (Joel & Wiener, 1994; Ridderinkhoff et al., 2004).

The aim of the study was to determine the brain activity of Poles during the Stroop test, and thus to increase the usefulness of the Stroop test in neuropsychological diagnostics.

MATERIAL AND METHODS

The study group consisted of 18 somatically and mentally healthy volunteers (ten women and eight men). The mean age of the group was 35.5. All participants demonstrated at least an average intellectual level, were right-handed, and correctly recognized colours. They were not addicted to any psychoactive substances. Several procedures were involved in the categorization of the experimental group, including a structured psychiatric interview, Raven's Progressive Matrices test (a version normalized for Polish conditions; Jaworowska & Szustrowa, 2007), the Edinburgh Handedness Inventory (Oldfield, 1971), and the "Naming Colours" clinical trial from the set of trials for the examination of cognitive processes in patients with brain damage by Włodzimierz Łucki (1995). The study was approved by Bioethics Committee of Collegium Medicum in Bydgoszcz, The Nicolaus Copernicus University in Toruń.

Study participants lay motionless in a PET scanner (Biograph mCT 128) with a blocked head under darkened conditions and completed the computer version of the Stroop task, which was adjusted for PET examination procedures. The task consisted of three parts. The resting part required focusing the eyes on a white cross displayed on a black background. The next two parts consisted of 36 words denoting colours, written in the colour congruent with the meaning of the word (non-interferential part A), or written in a colour incongruent with the meaning of the word (interferential part B). Participants responded verbally by naming what colour font the words appeared in. The testing procedure was based on the repeated measurement method; therefore, it consisted of a total of eight scans (R-A-R-B-R-2A-R-2B): four times at rest (R), two times during the performance of the non-interferential part of the Stroop task (A), and two times during the performance of the interferential part of the Stroop task (B). The subsequent parts of the test were separated by ten-minute breaks. Each subsequent part of the test was connected with the intravenous administration of the H_2O_{15} marker at a dose of 350-500 MBq in the form of a bolus. Fifteen seconds after the administration of the isotope, the scanning process started. This process lasted for another 60 seconds, during which participants performed a specific part of the cognitive task. The whole procedure was preceded by a CT examination (low dose) to correct the attenuation. The study was carried out in the Department of Nuclear Medicine in the Franciszek Łukaszczyk Oncology Centre in Bydgoszcz.

The neuroimaging data obtained directly from the PET examination was reconstructed into the DICOM format. The SPM8 software (Statistical Parametric Mapping – <http://www.fil.ion.ucl.ac.uk/spm/>) was used for voxel analysis. The standalone release of SPM8 (r5236) was used together with MATLAB Compiler Runtime (MCR) v 4.13, which did not require a license for the MATLAB software.

RESULTS

The results were analyzed for the entire study group. Hypotheses were tested using contrast analysis and the Student's t-test was used to evaluate differences between the mean brain activities in three experimental situations: at rest (R), during the completion of the first part of the Stroop task (A), and during the completion of the second part of the Stroop task (B). Differences were assumed to exist between brain activity at rest and during the Stroop task.

The results indicated that the peaks of activity during the interferential and non-interferential parts of the Stroop task did not always concern the same structures (Table 1). The highest activity during the interferential part of the Stroop task concerned the left supplementary motor area and the left and right precentral gyri, while the peak of activity during the non-interferential part of the Stroop task was highlighted in the right supplementary motor area and the right precentral gyrus. In addition, the peaks of activity referred to the right superior temporal gyrus and the areas of the left postcentral gyrus only during the non-interferential

Tab. 1. AAL coordinates, maximum t-value (local maxima) of the activated regions for the baseline vs. congruent(A) and baseline vs. incongruent (B) contrasts ($p < 0.05$ FWE)

Baseline vs. congruent			Baseline vs. incongruent		
T-value	Coordinates (X; Y; Z)	Peak voxel-level significant activations approximate region	T-value	Coordinates (X; Y; Z)	Peak voxel-level significant activations approximate region
5.49	39 47 28	<u>Frontal lobes</u> Frontal_Mid_R	5.2	42 47 28	<u>Frontal lobes</u> Frontal_Mid_R
8.12	0 -1 64	Supp_Motor_Area_R	8.2	-3 8 49	Supp_Motor_Area_L
11.07	54 -4 40	Precentral_R	10.9	-48 -7 40	Precentral_L
			10.5	57 -1 40	Precentral_R
9.71	-51 -7 40	<u>Parietal lobes</u> Postcentral_L	6.8	39 17 7	<u>Temporal lobes</u> Insula_R
7.51	57 -31 1	<u>Temporal lobes</u> Temporal_Sup_R	6.9	-2 -20 -4	<u>Subcortical</u> Thalamus_R
7.97	42 20 4	Insula_R	13.1	36 -61 -26	Cerebellum_Crus1_R
12.04	-36 -85 -17	<u>Subcortical:</u> Cerebellum_6_R			
4.98	15 -19 1	Thalamus_R			

Note: AAL- Anatomical Automatic Labeling; FWE- Family Wise Error Height threshold $T = 4.33$, Extent threshold of a cluster > 5 voxels

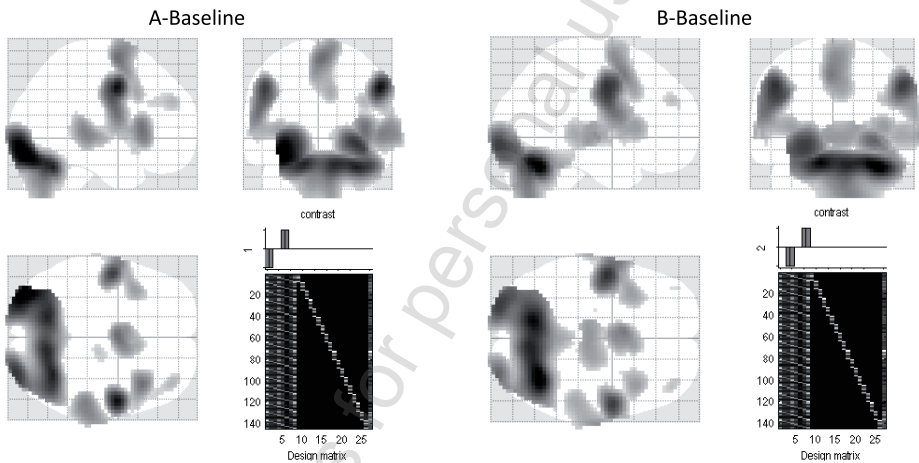


Fig. 1. Similar areas of brain activity during congruent (A) and incongruent (B) Stroop task performance — MNI templates. Height threshold $T = 4.33$; ($p < 0.5$ (FWE)); Extent threshold of a cluster > 5 voxels

part of the Stroop task. The peaks of activity in the cerebellum area concerned the superior frontal-medial lobule (cerebellum crus 1) on the right side for the interferential part of the Stroop task and the structures of the superior posterior-medial lobule on the right side (cerebellum crus 6) for the non-interferential part.

Although the peaks of activity did not always concern the same areas of the brain, both parts of the Stroop task were associated with the stimulation of similar areas of the brain (Figure 1).

In both cases, the frontal and temporal areas were bilaterally activated. They included prefrontal areas such as the superior frontal gyrus (Frontal_Sup_R) and, more medially, the structures of the supplementary motor area (Supp_Motor_Area_L/R) and the medial superior frontal gyrus (Frontal_Sup_Medial_L) of the cingulate gyrus (Cingulum_Mid_L/R). The activity of the right middle frontal gyrus (Frontal_Mid_R), which forms the dorsolateral prefrontal cortex, was also significant. The bilateral greater stimulation of the precentral gyrus (Precentral_L/R) and the inferior frontal gyrus (Frontal_Inf_Oper; Frontal_Inf_Tri; Front_Inf_Orb), which further extended from the junction of the frontal and the temporal lobes towards the middle and superior temporal gyri (Temporal_Mid_L/R, Temporal_Sup_L/R), the superior areas of the temporal pole (Temporal_Pole_Sup_L/R), and, more medially, the insular structures (Insula_L/R), is also noteworthy. The activity also concerned the vast area of both cerebellar hemispheres and some areas of the occipital lobes, including part of the superior, middle, and inferior occipital gyrus (Occipital_Sup_L/R; Occipital_Mid_L/R; Occipital_Inf_L/R), the lingual gyrus (Lingual_L/R), and the fusiform gyrus (Fusiform_L/R) in the left and right cerebral hemispheres.

DISCUSSION

It was initially believed that the completion of the Stroop test was associated primarily with the correct functioning of the frontal lobes (Perret, 1974). However, studies using neuroimaging techniques have changed this perspective, and each successive examination during exposure to the Stroop task provides valuable information on the functional system involved in its completion (Ravnkilde et al., 2002; Harrison et al., 2005; Bench et al., 1993; Carter et al., 1995; George et al., 1994; Bush et al., 1998; Peterson et al., 1999; Milham et al., 2001; Zysset et al., 2001; Ukai et al., 2002). Researchers, however, still devote their main interest to the role of the prefrontal areas that they consider crucial for the processes of dealing with cognitive conflict in the interferential part of the Stroop task, which requires a greater involvement of executive attention (Bush et al., 1998; Bush et al., 2000; Posner & Petersen, 1990; MacDonald et al., 2000). These studies often leave out or discuss in a general way the role of other areas, cortical and sub-cortical, that, along with the prefrontal areas, form the neurofunctional systems that are activated during the Stroop task. Little attention is paid to the fact that there are areas of the brain that are activated during both the non-interferential and the interferential part of the Stroop task, which may be proven by, in addition, the results of the experimental study presented in this paper. Therefore, if cognitive functions are treated as a result of the interaction of many areas of the brain, it can be assumed that damage to or the dysfunction of any of these areas, including those used during both parts of the Stroop task, will have a significant influence on test performance, including its interferential part. For this reason, the following section presents information collected from the subject literature in order to consider the possible significance of certain areas of the brain associ-

ated with the completion of both parts of the Stroop task, which have been stimulated during the conducted experimental study.

The activity of the occipital areas was the most expected in the case of exposure to both tasks, as the presented material was of a visual nature. Bilateral stimulation of the inferior, middle, and superior occipital cortex was related to the transmission of visual information and its processing and synthesis, as well as to the integration of visual information with information from other modalities. The lingual gyrus and the fusiform gyrus (the medial areas of the occipital lobes) were also involved in both parts of the Stroop task. Study results indicate their involvement in the identification and processing of colours (Wang et al., 2013). In both study situations, participants were asked to name the colour in which the word was written, which required the colour of the presented stimulus to be identified. There is also data that points to greater activity of the lingual gyrus during the interferential part of the Stroop task. This is explained by the need for a greater level of concentration in the interferential part, when identifying the colour of a written word that is incompatible with the meaning of the word, than in the non-interferential part, during which the word's colour is consistent with its meaning (Carter et al., 1995).

The organization of the temporal lobes is very complex. Therefore, although this area is usually treated as the hearing area, the results of studies of lesions to the temporal lobe area indicate that they have an impact not only on auditory perception, but also on visual perception, intellectual changes, and memory disorders specific to modality or a certain type of material (Walsh, 2000). The extension of the bilateral stimulation of the temporal lobe areas (Temporal_Mid_L/R, Temporal_Sup_L/R, Temporal_Pole_Sup_L/R) toward the medial area (Insula_L/R) during the completion of the Stroop tasks may be related to speech production. Wernicke's area, the area of understanding the speech of oneself and of others (Lezak, 1995; Walsh, 2000), is located in the posterior area of the superior, and partially middle, temporal gyrus (Temporal_Sup_L, Temporal_Mid_L). People with damage to this area can produce speech, but often use inadequate words. Wernicke's area has connections to the inferior frontal gyrus (Frontal_Inf_Oper_L), whose activity was also recorded during the completion of the test. Broca's motor speech area, which is related to the function of speech formulation and production, is located inside of Wernicke's area. Both areas are active during speech production, which was required by the completion of the Stroop task. Moreover, there is data that indicates the bilateral involvement of the superior temporal gyrus, along with the insula, in decision-making processes concerning the selection of appropriate responses (Paulus et al., 2005). Other data in the literature (Dronkers, 1996) would attribute the activity of the insula during the Stroop test to its involvement in planning, establishing sequences, and coordinating muscle contractions of the mouth when producing verbal responses.

As mentioned above, the prefrontal areas and their involvement in solving the cognitive conflict in the Stroop test are the primary interest for researchers of this subject. While reading the subject literature (Bush et al., 1998; Bush et al.,

2000; Posner & Petersen, 1990; MacDonald et al., 2000), one may often be under the impression that the dorsolateral prefrontal cortex and the cingulate cortex play an important role mainly during the completion of the interferential part of the Stroop task, and yet their activity is also recorded during the completion of the non-interferential part of the test (Carter et al., 1995; Posner & DiGirolamo, 1998). Based on data from previous studies, the activity of the dorsolateral prefrontal cortex (Frontal_Mid_R, Frontal_Sup_R) and its medial areas (Frontal_Sup_Medial_L, Cingulum_Mid_L, Cingulum_Mid_R) registered in the experimental study are associated with generally understood executive functions and short-term memory (Goldman-Rakic, 1987; Fuster, 1997; Owen, 1997; Miller & Cohen, 2001; Curtis & D'Esposito, 2004), as well as functions of executive attention (Posner & Petersen, 1990). The middle area of the cingulate gyrus corresponds anatomically to the dorsal area of the anterior cingulate cortex (Bush et al., 2000; Palomero-Gallagher et al., 2008). It has extensive connections with structures involved in cognitive processes, such as the DLPFC and the motor cortex areas. It is involved in the processes of monitoring and selecting responses, both of which are executive functions that are necessary for solving the situation of cognitive conflict, e.g., in the Stroop task. Milham et al. (2002) explain the activity of the cingulate cortex in both parts of the Stroop task by the occurrence of cognitive conflict in the non-interferential part. When a study participant is asked to name the colour in which a word is written, the participant is affected by information concerning the meaning of the word in addition to information about the colour of the font (congruent with the meaning of the word). This, consequently, requires stronger cognitive control, and thus stimulates the associated brain structures.

Also noteworthy is the fact that the completion of both test tasks causes stimulation in other frontal areas, e.g., the structures of the inferior frontal gyrus, the primary frontal motor cortex, and the supplementary motor area of the right and left hemispheres. In the source literature, both the right and left inferior frontal gyrus (Frontal_Inf_Oper_R/L; Frontal_Inf_Tri_R/L; Front_Inf_Orb_R/L) are associated with repressing automatic or habitual responses (Bunge et al., 2002; Durston et al., 2002; Menon et al., 2001; Garavan et al., 1999; Rubia et al., 1999; Konisi et al., 1998, 1999; Milham et al., 2002). Their activity during the test can be explained by the participant's need to repress the impulse to read out words during both Stroop tasks in favour of naming the colour in which the words were written.

The precentral gyrus of the motor cortex is the voluntary movement area, but through connections with Broca's area, it is indirectly involved in speech processes (Benzagmout et al., 2007; Fox et al., 2001; Wise et al., 1999). The supplementary motor area (SMA) is often indicated by researchers as an area that is activated during the Stroop task (Pardo et al., 1990; Ravnkilde et al., 2002). This structure is primarily associated with the planning, selection, and coordination of voluntary hand movements (Pickard & Strick, 2001). Therefore, its stimulation during the completion of tasks requiring manual responses, e.g., the pressing of a button, would be justified. It turns out, however, that the supplementary motor area is also activated in experimental situations where the answer

is given verbally. This may be explained by the involvement of this structure in speech production processes (Alario et al., 2006). There is also data that indicates the involvement of the supplementary motor area in the processes of repressing automated reactions, but the nature of this role is still unknown (review of research cited in Aron, 2010).

The activity of the cerebellum during the Stroop task allows us to have another look at this brain area in the context of its involvement in higher cognitive functions. The cerebellum was once merely considered to be an area responsible for coordinating movements initiated by the cerebral cortex and maintaining the balance of the body (Gołab & Jędrzejewski, 1992). However, studies on the functions of the cerebellum have shown that it is also involved in complex cognitive processes (Timmann & Daum 2007; Tirapu-Ustarroz et al., 2011; Tedesco et al., 2011; D'Angelo & Casali, 2012). Functions such as planning one's actions, controlling behaviour related to correcting one's actions and repressing automatic reactions, and the ability to switch attention were primarily associated with prefrontal areas of the cerebral cortex (Heyder et al., 2004). However, it turns out that these processes also involve subcortical structures, including the cerebellum (Jodzio, 2008). As a result of the clinical observations of patients with lesions to the cerebellum, Schmahmann and Sherman (1998) identified a group of symptoms related to the emotional and cognitive sphere appearing in these patients. This syndrome was called cerebellar cognitive affective syndrome (CCAS). It is manifested in the cognitive sphere by disorders in areas such as executive functions, visuospatial functions, and language functions. Over time, it has been found that one of the main functions of the cerebellum is the acquisition of new motor skills, including learning complex motor activities such as cycling or driving, which allows it to relieve the cerebral cortex. A very important element of such learning is the comparison of an intended activity with one that has been completed, which allows for error correction. Committing an error activates the cerebellum, or more specifically, Purkinje cells located in the cerebellum, for its correction in the feedback mode (Doya, 2000). The completion of the first and second parts of the Stroop task undoubtedly requires the comparison of the completed reaction with the required action as well as the possible correction of committed errors, which can activate the cerebellar structures. In addition, the cerebellum has been proven to be involved in language functions, including the processes requiring rapid naming. Deficits in this skill have been associated with cerebellar dysfunctions in people with dyslexia (Dencla & Rudel, 1976; Raberger, 2003; Nicolson et al., 2001). The rapid colour naming required during the completion of both parts of the Stroop test forced by, among other things, the limited time of exposure to the stimulus, can also result in the activation of the cerebellar structures. If, in accordance with previous conceptions, the cerebellum was to be treated as the motor coordination area, its activity during the completion of the Stroop task can be linked to the motor aspect of the action of giving verbal answers, where the cerebellum is responsible for the fluency of speech and its damage causes speech impairment, a symptom of which is scanning speech.

However, in the context of the above-cited scientific reports, it seems that the activity of the cerebellum during the Stroop test was not solely associated with speech motor skills.

Another subcortical area that was activated during both Stroop tasks was the thalamus. This activity is fully justified because of the responsibility of this cerebral structure for wakefulness and general stimulation, which is necessary for performing any conscious action. Results of neuroimaging studies (Fiset et al., 1999; Kajimura et al., 1999; Kimomura et al., 1996; Paus et al., 1997) confirm the involvement of the thalamus in the above processes, as well as its involvement in tasks that require the activation of attention processes. According to some researchers, the increase in the activity of the thalamus is closely related to the increase in the requirements of cognitive situations connected with the involvement of attention processes (Carter et al., 1995).

The results and data from earlier neuroimaging studies presented in this paper indicate that several cortical areas and some subcortical structures forming a neurofunctional system are involved in the Stroop task. The areas of the DLPFC and the cingulate gyrus should be treated in this case as elements of this system, without diminishing their significant involvement in the processes of executive attention. However, in addition to looking for neural correlates of specific cognitive functions involved in the Stroop test, an important issue for the diagnostic application of this neuropsychological tool is the translation of knowledge from neuroimaging studies into quality markers of test performance. After the question of which structures are responsible for specific cognitive functions, the next important question is how damage to a given structure affects test performance. Such a question underlines the role of all of the structures that are active during the Stroop test, including those that are used during both the interferential and non-interferential parts of the Stroop task.

The primary limitation of the study, which could to a certain extent distort the obtained results, was the relatively small number of participants, even though similar numbers can be found in an analysis of the literature in the field of neuroimaging (Harrison et al., 2005; Egnér & Hirsh, 2005; Zysset et al., 2001; Pardo et al., 1990). However, the greater the number of measurements, the greater the grounds for statistical inference. Therefore, in order to increase the number of measurements, study participants performed both the non-interferential and interferential parts of the Stroop task twice. This could have reduced the level of the induced cognitive conflict as a result of the learning process (practice acquisition) in the second measurements during the second part of the task. Consequently, this may have weakened the image of activity of certain areas of the brain during the statistical averaging of data. The issue of the impact of experience on changes in patterns of brain activity was raised in the study of Harrison et al. (2005). Experience in coping with situations of interference reduces the level of cognitive conflict, causing changes in the involvement of some areas that are important in conducting the interferential part of the Stroop task. However, repeating the measurement is necessary from a technical point of view, as

it significantly improves and strengthens the quality of the obtained image of the brain in neuroimaging examinations.

CONCLUSION

The completion of the non-interferential and interferential parts of the Stroop task is linked to the activity of similar brain structures. In addition to the prefrontal areas, which have so far inspired the greatest interest among researchers in terms of their involvement in solving cognitive conflict, other cortical areas are involved in the completion of the Stroop test. These include the temporal lobes and the motor cortex, including the supplementary motor area. The activity of the subcortical structures, including the cerebellum and the thalamus, also turns out to be significant. Together, they form a neurofunctional system. It can therefore be concluded that structural damage to or the dysfunction of any of the elements of this system would affect a person's performance on the Stroop test.

REFERENCES

- Alario, F.X., Chainay, H., Lehericy, S., Cohen, L. (2006). The role of SMA in word production. *Brain Research* 1076, 129-143.
- Aron AR (2010) From reactive to proactive and selective control: developing a richer model for stopping inappropriate responses. *Biol Psychiatry, Advance online publication*. Retrieved November 16, 2010
- Raberger, 2003; Nicolson i wsp., 2001
- Banich, M. T., Milham, M. P., Atchley, R., Cohen, N. J., Webb, A., Wszalek, T., i in. (2000). fMRI studies of Stroop tasks reveal unique roles of anterior and posterior brain systems in attentional selection. *Journal of Cognitive Neuroscience*, 12, 988-1000.
- Bench, C. J., Frith C.D, Grasby P.M, Friston K.J, Paulesu E, Frackowiak R.S, Dolan R.J. (1993). Investigations of the functional anatomy of attention using the Stroop test. *Neuropsychologia*, 31, 907-922.
- Benzagmout M., Gatignol P., Duffau H.(2007). Resection of World Health Organization Grade II Gliomas involving Broca's area: methodological and functional considerations. *Neurosurgery*, 61: 741-753
- Bunge S.A, Dudukovic N.M, Thomason M.E, Vaidya C.J, Gabrieli J.D.E. (2002). Immature frontal lobe contributions to cognitive control in children: evidence from fMRI. *Neuron*, 33, 301-311.
- Bush G, Whalen P.J, Rosen B.R, Jenike M.A., McInerney S.C., Rauch S.L. (1998). The counting Stroop: An interference task specialized for functional neuroimaging- validation study with functional MRI. *Hum Brain Mapping*, 6, 270 -282.
- Bush, G., Luu, P., Posner, M. I. (2000). Cognitive and emotional influences in anterior cingulate cortex. *Trends in Cognitive Science*, 4, 215-222.
- Carter C.S., MacDonald A.M., Botvinick M., Ross L.L., Stenger V.A., Noll D., Cohen J. D. (2000) Parsing executive processes: strategic vs. evaluative functions of the anterior cingulate cortex. *Proc Natl Acad Sci U S A*, 97, 1944-1948.
- Carter, C. S., Mintun, M., Cohen, J. D. (1995). Interference and facilitation effects during selective attention: An H215O PET study of Stroop task performance. *NeuroImage*, 2, 264-272.
- Curtis C.E, D'Esposito M.(2004). The effects of prefrontal lesions on working memory performance and theory. *Cogn Affect Behav Neurosci*;4,528-539.
- D'Angelo E, Casali S.(2012). Seeking a unified framework for cerebellar function and dysfunction: from circuit operations to cognition. *Front Neural Circuits*, 6, 116
- Denckla, M.B. Rudel, R.G. (1976) Rapid 'Automatized' naming (R.A.N.). Dyslexia differentiated from other learning disabilities. *Neuropsychologia* 14, 471-479

- Doya, K. (2000). Complementary roles of basal ganglia and cerebellum in learning and motor control. *Current Opinion in Neurobiology* 10, 732-739
- Dronkers, F. (1996). A new brain region for coordinating speech articulation. *Nature*, 384, 159-161.
- Durston S, Thomas KM, Worden MS, Casey BJ (2002b). The effect of preceding context on inhibition: an event-related fMRI study. *Neuroimage*, 16, 449–453.
- Durston S, Thomas KM, Yang YH, Ulug AM, Zimmerman RD, Casey BJ (2002a). A neural basis for the development of inhibitory control. *Dev Sci* 5, F9–F16.
- Fiset, P., Paus, T., Daloze, T., Plourde, G., Meuret, P., Bonhomme, V., Hajj-Ali, N., Backmann, S.B., Evans, A.C.(1999) Brain mechanisms of propofol-induced loss of consciousness in humans: a positron emission tomographic study. *J. Neurosci.* 19, 5506–5513
- Fox R.J., Kasner S.E., Chatterjee A., Chalela J.A.(2001). Aphemia: an isolated disorder of articulation. *Clin. Neurol. Neurosurg.*, 103: 123-126.
- Fuster J.M. (1997). The prefrontal cortex. *New York: Raven Press.*
- Garavan, H., Ross, T. J., Stein, E. A. (1999). Right hemispheric dominance of inhibitory control: An event-related fMRI study. *Proceedings of the National Academy of Sciences, USA*, 96, 8301–8306
- George MS, Ketter T.A., Parekh P.I., Rosinsky N, Ring H., Casey B.J. et al. (1994). Regional brain activity when selecting a response despite interference: An H2150 PET study of the Stroop and the emotional Stroop. *Hum Brain Mapping* 1, 194–209
- Gołąb, B.K., Jędrzejewski, K. (1992). Anatomia czynnościowa ośrodkowego układu nerwowego. Warszawa: PZWL.
- Goldman-Rakic P.S.(1987). Circuitry of primate prefrontal cortex and regulation of behavior by representational memory. W: F. Plum, U. Muncastle, (ed.), *Handbook of physiology* (pp.373-417). *Washington: American Physiological Society.*
- Gruber, S. A., Rogowska, J., Holcomb, P., Soraci, S. Yurgelun-Todd, D. (2002). Stroop performance in normal control subjects: an fMRI study. *NeuroImage* 16: 349-360.
- Harrison, B.J., Shaw, M., Yucel, M., Purcell, R., Warrick, J. B., Strother, S.C., Egan, G., Oliver, J.S., Nathan, P.J., Pantelis, C.(2005). *Functional connectivity during Stroop task performance. Neuroimage* 24: 181-191.
- Heyder K, Suchan B, Daum I. (2004). Cortico-subcortical contributions to executive control. *Acta Psychol*, 115, 271-289.
- Jaworowska, A., Szutrowa, T. (2007). *Podręcznik do Testu Matrycy Ravena w wersji standard.* Warszawa: Pracownia Testów Psychologicznych Polskiego Towarzystwa Psychologicznego.
- Jodzio K.(2008). *Neuropsychologia intencjonalnego działania. Koncepcje funkcji wykonawczych.* Warszawa: Wydawnictwo Naukowe Scholar.
- Joel, D., Wiener, I. (1994). The organization of the basal ganglia-thalamo cortical circuits: open interconnected rather than closed segregated. *Neuroscience*, 63, 363-379.
- Kajimura, N., Uchiyama, M., Takayama, Y. i wsp. S. Uchida, S., Uema, T., Kato, M., Sekimoto, M., Watanabe, T, Nakajima, T, Horikoshi, S., Ogawa, K., Nishikawa, M., Hiroki, M., Kudo, Y., Matsuda, H., Okawa, M., Takahashi, K. (1999). Activity of midbrain reticular formation and neocortex during the progression of human non-rapid eye movement sleep. *J. Neurosci.* 19, 10065–10073.
- Kimomura, S, Larsson, J., Gulyas, B., Roland, B.E.. (1996). Activation of the human reticular formation and thalamic intralaminar nuclei, *Science* 271 (1996) 512–515
- Konishi S, Nakajima K, Uchida I, Kameyama M, Nakahara K, Sekihara K, Miyashita Y. (1998). Transient activation of inferior prefrontal cortex during cognitive set shifting. *Nat Neurosci.* 1, 80-84.
- Konishi, S., Nakajima, K., Uchida, I., Kikyo, H., Kameyama, M., & Miyashita, Y. (1999). Common inhibitory mechanism in human inferior prefrontal cortex revealed by event-related functional MRI. *Brain*, 122, 981–991
- Leung, H.-C., Skudlarski, P., Gatenby, J. C., Peterson, B. S., Gore, J. C. (2000). An event-related functional MRI study of the Stroop color word interference task. *Cerebral Cortex*, 10, 552-560.
- Lezak, M. D., (1995). *Neuropsychological assessment.* New York: Oxford University Press.

- Łucki W.: Zestaw prób do badania procesów poznawczych u pacjentów z uszkodzeniami mózgu. Pracownia Testów Psychologicznych PTP, Warszawa 1995.
- Markowska A. (2013) Attention processes in mindfulness: the influence of mindfulness intervention on performing Stroop based tasks. *Acta Neuropsychologica* 11(4): 333-344.
- MacDonald, A. W., III, Cohen, J. D., Stenger, V. A., & Carter, C. S. (2000). Dissociating the role of the dorsolateral prefrontal and anterior cingulate cortex in cognitive control. *Science*, 288, 1835-1838.
- MacLeod, C.M., (1991). Half a century of research on the Stroop effect, an integrative review. *Psychol. Bull.* 109, 163– 203.
- Menon, V., Adleman, N. E., White, C. D., Glover, G. H., Reiss, A. L. (2001). *Human Brain Mapping*, 12, 131–143
- Milham, M. P., Banich, M. T., Barad, V. (2003). Competition for priority in processing increases prefrontal cortex's involvement in topdown control: An event-related fMRI study of the Stroop task. *Cognitive Brain Research*, 17, 212-222.
- Milham, M. P., Banich, M. T., Webb, A., Barad, V., Cohen, N. J., Wszalek, T., Kramer, A. F. (2001). The relative involvement of anterior cingulate and prefrontal cortex in attentional control depends on nature of conflict. *Cognitive Brain Research*, 12, 467-473.
- Milham, M., Erickson, K.I., Banich, M., Kramer, A., Webb, A., Wszalek, T., Cohen, N. (2002). Attentional control in the aging brain: insights from an fMRI study of the Stroop task. *Brain Cogn.*, 49 (3), 277–296.
- Miller EK, Cohen JD (2001). An integrative theory of prefrontal cortex function. *Annu Rev Neurosci*; 24, 167-202
- Nee D.E, Wager T.D, Jonides J. (2007). A meta-analysis of neuroimaging studies of interference resolution. *Cognitive Affective and Behavioral Neuroscience*, 7 (1), 1-17.
- Oldfield, R. C. (1971). The assessment and analysis of handedness: The Edinburgh inventory. *Neuropsychologia*, 9, 97-113
- Owen A.M.(1997). The functional organization of working memory processes within human lateral frontal cortex: the contribution of functional neuroimaging. *Eur J Neurosci*; 9, 1329-1339.
- Palomero-Gallagher, N., Mohlberg H., Zilles, K., et al.(2008). Cytology and receptor architecture of human anterior cingulate cortex. *J Comp Neurol*, 508, 906–926
- Pardo, J., Pardo, P., Janer, IC, Raichle, M. (1990). The anterior cingulate cortex mediates processing selection in the Stroop attentional conflict paradigm. *Proc Nat Acad Sci.* 87: 256-259.
- Paulus, M. P., Justin T., Feinstein, S. Leland, D., Simmons, A. N. (2005). Superior temporal gyrus and insula provide response and outcome-dependent information
- Paus, T., Zatorre, R.J., Hofle, N., Caramanos, Z., Gotman, J, Salhouse, M., Petrides, T.A., Evans, A.C. (1997). Time-related changes in neural systems underlying attention and arousal during the performance of an auditory vigilance task. *J. Cogn. Neurosci.* 9, 392–408.
- Perret, E. (1974). The left frontal lobe of man and the suppression of habitual responses in verbal categorical behavior. *Neuropsychology*, 12, 323-330.
- Peterson, B. S., Skudlarski, P., Gatenby, J. C., Zhang, H., Anderson, A. W., Gore, J. C. (1999). An fMRI study of Stroop word-color interference: Evidence for cingulate subregions subserving multiple distributed attentional systems. *Biological Psychiatry*, 45, 1237–1258.
- Picard N, Strick PL (2001). Imaging the premotor areas. *Curr Opin Neurobiol* 11, 663–672
- Posner, M. I., DiGirolamo, G. J. (1998). Executive attention: Conflict, target detection and cognitive control. W: R. Parasuraman (ed.), *The attentive brain* (pp. 401–423). Cambridge, MA: MIT Press.
- Posner, M. I., Petersen, S. E. (1990). The attention system of the human brain. *Annual Review of Neuroscience*, 13, 25–41.
- Ravnkilde, B., Videbeck P., Rosenberg1 R., Gjedde A., Gade A. (2002). Putative Tests of Frontal Lobe Function: A PET-Study of Brain Activation During Stroop's Test and Verbal Fluency. *Journal of Clinical and Experimental Neuropsychology*, 24 (6), 534-547
- Ridderinkhof K.R, Ullsperger M, Crone E.A, Nieuwenhuis S. (2004). The role of the medial frontal cortex in cognitive control. *Science* 306: 443–447.

- Rubia, K., Overmeyer, S. O., Taylor, E., Brammer, M., Williams, S., Simmons, A., et al. (1999). Hypofrontality in attention deficit hyperactivity disorder during higher order motor control: A study with functional MRI. *American Journal of Psychiatry*, 156, 891–896
- Schmahmann JD, Sherman JC. (1998). The cerebellar cognitive affective syndrome. *Brain* 121, 561-579.
- Stroop J. R. (1935). Studies of interference in serial verbal reactions. *Journal of Experimental Psychology*;18: 643–61.
- Taylor, S.F., Kornblum, S., Lauber, E.J., Minoshima, S., Koeppe, R.A. (1997) Isolation of specific interference processing in Stroop task: PET activation Studies. *Neuroimage* 6: 81-92.
- Tedesco AM, Chiricozzi FR, Clausi S, et al. (2011). The cerebellar cognitive profile. *Brain*, 134: 3672-3683.
- Tzourio-Mazoyer, N., Landeau, B., Papathanassiou, D., Crivello, F., Etard, O., Delcroix, N., Mazoyer, B., Joliot, M. (2002). Automated Anatomical Labeling of activations in SPM using a Macroscopic Anatomical Parcellation of the MNI MRI single-subject brain. *NeuroImage* 15 (1), 273–289.
- Timmann D, Daum I. (2007). Cerebellar contributions to cognitive functions: a progress report after two decades of research.. *Cerebellum*; 6, 159-162
- Tirapu-Ustarroz J, Luna-Lario P, Iglesias-Fernandez MD, Hernaez-Goni P. (2011). Cerebellar contributions to cognitive process: current advances. *Rev Neurol*; 53, 301-315.
- Ukai S, Shinosaki K, Ishii R, Ogawa A, Mizuno-Matsumoto Y, Inouye T, Hirabuki N, Yoshimine T, Robinson SE, Takeda M. (2002). Parallel distributed processing neuroimaging in the Stroop task using spatially filtered magnetoencephalography analysis. *Neurosci Lett.*, 334, 9-12.
- Vendrell, P., Junque, C., Pujol, J., Jurado, M.A., Molet, J., Grafman, J. (1995). The role of prefrontal regions in the Stroop task. *Neuropsychologia* 33 (3): 341- 352.
- Walsh, K. (2000). *Neuropsychologia kliniczna*. Warszawa: PWN.
- Wang, X; Han, Z.; He, Y., Caramazza, A., Bi, Y. (2013). Where color rests: Spontaneous brain activity of bilateral fusiform and lingual regions predicts object color knowledge performance. *Neuroimage*, 76:252-263
- Wise R.J., Greene J., Buchel C., Scott S.K. (1999). Brain regions involved in articulation. *Lancet*, 2: 395-4
- Zysset, S., Muller, K., Lohmann, G., Yves von Cramon, D. (2001). Color – word matching Stroop task: separating interference and response conflict. *NeuroImage* 13: 29-36.

Address for correspondence

Anita Markowska

Department of Psychiatry Nursing, Collegium Medicum,

Nicolaus Copernicus University in Toruń

Łukasiewicza 1, str.

85-821 Bydgoszcz, Poland

e-mail: anita.markowska@cm.umk.pl